

Effect of computerized delivery intraligamental injection in primary molars on their corresponding permanent tooth buds

MALKA ASHKENAZI¹, SIGALIT BLUMER² & ILANA ELI³

¹Department of Pediatric Dentistry, Tel Aviv University; currently Private Practice, Tel Aviv, Israel, ²Department of Pediatric Dentistry, The Maurice and Gabriela Goldschleger School of Dental Medicine, Tel Aviv University, Tel Aviv, Israel, and

³Department of Oral Rehabilitation, The Maurice and Gabriela Goldschleger School of Dental Medicine, Tel Aviv University, Tel Aviv, Israel

International Journal of Paediatric Dentistry 2010; 20: 270–275

Objective. To evaluate the prevalence of developmental disturbances in permanent teeth in which buds were exposed to intraligamental injection (ILI) delivered by a computer controlled local anaesthetic delivery (C-CLAD).

Methods. The study population consisted of 78 children (age 4.1–12.8 years) who received ILI–C-CLAD to 166 primary molars. A structured form was designed to include information regarding age at treatment, gender, type of treated tooth, tooth location, type of dental treatment, and type of developmental disturbance(s) present in the asso-

ciated permanent tooth. Teeth, which received regular anaesthesia or were not anaesthetized by local anaesthesia, served as controls.

Results. Five children had developmental defects. In C-CLAD–ILI exposed teeth, one child had two hypomaturational defects. The corresponding primary teeth were extracted. No defects were found on the control side. In two children, hypoplastic defects were found only in the control teeth (one in each child). One suffered from a dentoalveolar abscess in the corresponding primary tooth. Diffuse hypomaturational defects were found in two children on both the C-CLAD–ILI exposed and control sides.

Conclusion. In the primary dentition, C-CLAD–ILI does not increase the danger of developmental disturbances to the underlying permanent dental bud.

Introduction

Intraligamental anaesthesia delivered by a high pressure syringe is often associated with damage to the periodontal tissue. This results from the physical trauma formed at the time of injection and from the cytotoxic effects of the anaesthesia^{1–7}. Damage heals within a few weeks^{1,6}. Prolonged postoperative dental pain, which can last up to 4 weeks, is one implication of periodontal tissue damage^{2,6,8–10}. Developmental disturbances to the underlying permanent tooth buds is another implication.

In one study a high pressure intraligamental anaesthesia was used to anaesthetize 16 monkey primary teeth⁵. Teeth in the contralateral positions were not injected and served as a control. Hypoplasia or hypomineralization defects developed in 15 of the permanent

teeth, but none in the controls. The position of the enamel lesions indicated that the disturbance occurred at the same time on all affected teeth⁵. Accordingly, textbooks in paediatric dentistry and local anaesthesia warned paediatric dentists about the danger of administering intraligamental anaesthesia to primary teeth in young children^{11,12}.

Intraligamental injection (ILI) delivered by a computer controlled local anaesthesia delivery (C-CLAD–ILI; Wand or STA, Milestone Scientific, Inc., Deerfield, IL, USA) is a relatively new technique to anaesthetize primary teeth and its use is gathering momentum^{13–18}.

Although during intraligamental anaesthesia by a high pressure syringe or by C-CLAD the local anaesthetic solution is injected into the same area (the entrance of the periodontal ligament space), the two techniques are completely different^{13–15}. Most children show comparable low pain-related behaviour during C-CLAD–ILI and infiltration to the maxillary molars^{13,15}. Moreover, in contrast to high

Correspondence to:

Dr. Malka Ashkenazi, 7a Haim Gilad St. Petach-Tikva, Israel. E-mail: malka.ashkenazi@gmail.com

pressure intraligamental anaesthesia, C-CLAD-ILI does not increase the prevalence or intensity of postoperative dental pain as compared to conventional injections administered for routine operative treatments in children^{18,19}.

One of the reasons that dentists avoid using this technique in primary dentition is their concern to the effect of this technique on the development of the corresponding permanent tooth buds. To date, the possible long-term effects of C-CLAD-ILI to the underlying developing tooth buds have not been evaluated. The aim of this study was to evaluate the effect of C-CLAD-ILI anaesthesia on the prevalence of developmental disturbances in the underlying developing tooth buds.

Material and methods

The study population consisted of 78 children from all socioeconomic levels who attended routine treatment in two specialized paediatric dental clinics. Children received C-CLAD-ILI to anaesthetize their primary first or second molars during the years 1999–2007. Seventy-two of the participating children, participated also in previous published studies about the effectiveness of C-CLAD-ILI in primary molars^{16–18}.

Children were retrospectively identified and evaluated 0.5 to 8 years post-treatment. The erupted permanent premolars, previously exposed to C-CLAD-ILI, were examined for developmental disturbances. Analogue premolars not exposed to C-CLAD-ILI served as controls. Teeth on the control side were either exposed to routine infiltration or mandibular block during their developmental stage or untreated.

Diagnosis of developmental disturbances in erupted teeth

A structured form was designed to include information regarding date of birth, gender, age at receiving the C-CLAD-ILI, type of treated tooth (primary mandibular or maxillary first or second molar), type of local anaesthesia administered (routine infiltration, mandibular block, or C-CLAD-ILI), and dental

treatment (restorations, stainless steel crown, pulpal therapy, or extraction).

Type of developmental disturbance present in the permanent premolars was recorded according to Clarkson and O'Mullane²⁰, and included the following parameters:

- (a) Type of defect: normal, demarcated opacity (white/cream or yellow/brown), diffuse opacity, hypoplasia, and others
- (b) Extent of defect: less than 1/3, at least 1/3 or <2/3, at least 2/3
- (c) Location of defect: gingival half, incisal half, occlusal, cuspal
- (d) Size of the developmental disturbances: <2 mm², 2–4 mm², and >4 mm

Children were examined by the two paediatric dentists (MA and SB) who had initially treated them. To calibrate, the examiners were given 54 slides of teeth with clinical developmental disturbances in the enamel (courtesy of Prof. Haim Sarnat, former Head of the Department of Pediatric Dentistry, Tel Aviv University). Each examiner independently evaluated and assessed each slide. In cases of disagreement, the issue was discussed to achieve an unanimous decision.

The Ethics Committee of Tel Aviv University approved the study.

Statistical analysis

The differences between groups was analysed by using McNemar test. The power calculations were conducted using Compare2 version 1.21 (Sagebrush Press, Salt Lake City, UT, USA, 2001).

Results

Population description

Mean age of the children was 8.8 ± 2.45 . Teeth exposed to C-CLAD-ILI injection before eruption included 76 primary first molars, 90 primary second molars (total 166 permanent teeth).

Description of study groups

Tooth distribution according to age at treatment is shown in Fig. 1. There were 81

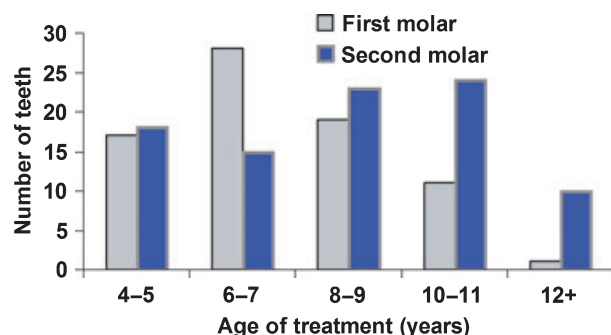


Fig. 1. Distribution of treated primary teeth according to age at the time of treatment.

permanent teeth (32 first and 49 second premolars) exposed to C-CLAD-ILI before developmental completion of their crowns (first premolar at 5–6 years; second premolar at 6–7 years)²¹.

Table 1 shows the tooth distribution in the control and in the C-CLAD-ILI exposed groups (according to location, type of local anaesthesia, and treatment). Periapical or inter-radicular lesions were the reason for 40 of the 42 extracted teeth.

Developmental disturbances

C-CLAD-ILI exposed permanent teeth. A demarcated white opacity defect (2 mm² on the incisal half of the buccal aspect of the buccal cusp)

Table 1. Distribution of C-CLAD-ILI exposed and control teeth according to location, type of received local anaesthesia, and type of treatment (n = 166).

Variables	Primary molars			
	First		Second	
	C-CLAD-ILI	Control	C-CLAD-ILI	Control
Distribution				
Upper arch	16	49	24	59
Lower arch	60	27	66	31
Anaesthesia				
None	0	56	0	53
Local infiltration	0	18	0	32
Mandibular block	0	2	0	5
C-CLAD-ILI	76	0	90	0
Treatment				
Restoration	56	17	66	27
Pulp	6	0	4	1
Root canal	—	—	1	3
Extraction	14	3	19	6
No treatment	0	56	0	53

was found in two permanent mandibular premolars (right and left) of a 10-year-old boy (patient A). The primary teeth in these regions were extracted due to severe crowding in the lower anterior segment. Primary mandibular canines and primary mandibular first molars (right and left) were extracted when the child was 6.8 years old, in a 1-week interval.

Control group. Small hypoplastic defects (pitted, 1–2 mm) were found in the permanent maxillary right and left first premolars (at the incisal half of the buccal cusp) of a 10.3-year-old boy (patient B). The corresponding primary teeth were not treated. The patient received C-CLAD-ILI to restore his primary mandibular second molars.

A hypoplastic lesion (2–4 mm², located at the occlusal half of the buccal aspect of the buccal cusp) was found on the permanent mandibular second premolar (tooth 35) of a 13-year-old girl (patient C). The patient received a mandibular block for root canal and a pre-formed crown in the corresponding primary molar (tooth 75) when the child was 6.2 years old. Since this primary molar had an acute dentoalveolar abscess accompanied by swelling, root canal treatment was carried out. At 10 years, the child received a mandibular block and the tooth was extracted. The corresponding second permanent premolar (tooth number 35) was starting to erupt ectopically. It is noteworthy that another primary tooth (tooth 85) was treated by pulpotomy with C-CLAD-ILI anaesthesia at the same age. The corresponding permanent premolar of this tooth was intact.

Control and C-CLAD-ILI exposed teeth. Two girls (8.9 years, patient D and 12.4 years old, patient E) showed light white diffuse opacities on the tip of the cusps in all their permanent teeth (incisors, premolars, and molars). Disturbances resembled hypomaturation amelogenesis imperfecta, snow-capped type. Each girl received C-CLAD-ILI anaesthesia and restorations in only one of their primary mandibular second molars.

Statistical analysis. No differences were found in the prevalence of hypoplasia between

control and experimental group ($P = 1$). In addition, our study had a 90% power to examine the equivalence hypothesis that the risk of hypoplasia in treated teeth is not significantly ($P < 0.05$) higher than 9% compared with untreated teeth.

Discussion

High pressure ILI may damage the underlying developmental dental buds of the permanent teeth in primary teeth⁵. In daily paediatric dental practices, this has had a considerable impact. Two important textbooks, which refer to local anaesthesia and paediatric dentistry, warns of the potential danger to the underlying permanent tooth bud when using ILI in primary teeth in young children^{11,12}. While never replicated, the study of Brännström *et al.*⁵ persuaded the paediatric dental community to abandon intraligamental anaesthesia and to use conventional modes of local anaesthesia in children. In this study, the long-term effect of the intraligamental injection delivered by C-CLAD was clinically evaluated.

The control group included corresponding teeth in the same child that were untreated or exposed to routine infiltration (maxillary premolars) or mandibular block (premolars). High pressure ILI was not used as a control since it is unethical to expose young children to a possible damaging procedure.

Several results were found when the presence of possible developmental disturbances in permanent teeth exposed to C-CLAD-ILI during their developmental stage, were evaluated. However, none were directly associated with the C-CLAD-ILI anaesthesia.

The small demarcated white opacity in patient A could be attributed to the type of anaesthesia and type of treatment. Since treatment included extraction of extremely crowded primary canines and molars, the opacity defects could have been attributed to the damage of the dental bud during extraction and not necessarily to the type of anaesthesia used. Interestingly, the boy's age (6.10 years) at the time of treatment was according to the dental age after completion of crown development of the permanent

mandibular premolars. This is in accordance with Williamson²² who showed radiological and histological enamel hypoplasia in unerupted premolars following extraction of their predecessor primary molars at age 4–6 years old. These premolars showed evidence of mechanical deformation. In the histological specimens there was seen alteration in the alignment of the dentinal tissue or a demarcated line which separated pretraumatic from post-traumatic dentine. These changes were interpreted as a bodily shift of the calcified part of the forming crown in relation to the as yet unclassified part. These results are also in accordance with Wright and Butler²³ who claim that hypomaturational defects in enamel of normal thickness occur during early maturation after secretion of the enamel protein and initial mineralization.

Two children (patients B, C, controls) showed hypoplastic defects in their permanent premolars. In patient B, the hypoplastic defect in the premolars could not be attributed to the type of local anaesthesia since the location was in the upper arch while C-CLAD-ILI was delivered to the lower arch. The primary teeth associated with the affected permanent premolars were not exposed to any operative treatment. This emphasizes the difficulty in determining a specific insult to each developmental defect. The second hypoplastic defect (patient C) was in a permanent tooth in which the corresponding primary tooth had an acute dental abscess. The child had root canal treatment at 6 years of age (during development of its corresponding primary molars). This defect could be related to the damage caused by the acute dentoalveolar abscess and/or to the root canal treatment.

The diffuse white opacities in all new erupting permanent teeth in patients D and E did not reflect an incremental pattern and could not be attributed to the type of anaesthesia but rather to mineralization disturbances.

From this data, it may be concluded that the ILI delivered by a C-CLAD does not damage the corresponding permanent tooth bud. Differences in the prevalence of developmental disturbances between high pressure ILI

(as reported by Brännström *et al.*⁵) and the C-CLAD-ILI anaesthesia used in this study may be in the higher biological compatibility of C-CLAD-ILI, which does not induce periodontal or bone damage.

Another study¹⁷ showed that children exhibited low pain-related behaviour and low levels of stress during and immediately after C-CLAD-ILI anaesthesia. These children also reported a comparable incidence of post-treatment dental pain (38%) after infiltration anaesthesia¹⁸. It could be speculated that the slow administered local anaesthetic solution by the C-CLAD does not cause damage to the periodontal apparatus (in contrast to high pressure ILI).

It can be concluded that although ILI administered by C-CLAD and high pressure syringe are injected into the same place, C-CLAD-ILI does not damage the underlying permanent dental bud in children 4.1 years or older. Notwithstanding, younger children who receive C-CLAD-ILI to anaesthetize their primary molars should be routinely followed-up to rule out developmental defects in their permanent premolars.

What this paper adds

- Intraligamentary injection delivered to primary molars by a C-CLAD does not damage the underlying permanent dental bud in children 4.1 years or older.

Why this paper important to paediatric dentists

- Paediatric dentist will be free to use C-CLAD-ILI in primary molars in children aged 4.1 and older, without worrying about the consequence of this technique on the underlying developing dental bud.
- Increasing usage of C-CLAD-ILI in children will increase the cooperation of the children during administration of local anaesthesia
 - decrease the prevalence of traumatic injuries to soft tissue following insertion of local anaesthesia
 - decrease the discomfort associated with the feeling of anaesthesia of soft tissue.

References

- 1 Brännström M, Nordenvall KJ, Hedstrom KG. Periodontal tissue changes after intraligamentary anesthesia. *ASDC J Dent Child* 1982; **49**: 417–423.
- 2 Quilici DL. Contraindications in the use of the periodontal ligament injection. *Compend Contin Educ* 1990; **9**: 96–100.

- 3 Saroff SA, Chasens AI, Orlowski W, Doyle JL. External tooth resorption following periodontal ligament injection. *J Oral Med* 1986; **41**: 201–203.
- 4 Walton RE. Distribution of solutions with the periodontal ligament injection: clinical, anatomical and histological evidence. *J Endod* 1986; **12**: 492–500.
- 5 Brännström M, Lindskog S, Nordenvall KJ. Enamel hypoplasia in permanent teeth induced by periodontal ligament anesthesia of primary teeth. *J Am Dent Assoc* 1984; **109**: 735–736.
- 6 Schleider JR, Reader A, Beck M, Meyers WJ. The periodontal ligament injection: A comparison of 2% lidocaine, 3% mepivacaine, and 1:100,000 epinephrine to 2% lidocaine with 1:100,000 epinephrine in human mandibular premolars. *J Endod* 1988; **14**: 397–404.
- 7 Kim S. Ligamentary injection. A physiological explanation of its efficacy. *J Endod* 1986; **12**: 486–491.
- 8 White JJ, Reader AI, Beck M, Meyers WJ. The periodontal ligament injection: A comparison of efficacy in human maxillary and mandibular teeth. *J Endod* 1988; **14**: 508–514.
- 9 Faulkner RK. The high-pressure periodontal ligament injection. *Br Dent J* 1983; **154**: 103–105.
- 10 Kaufman E, Galili D, Garfunkel AA. Intraligamentary anesthesia: a clinical study. *J Prosthet Dent* 1983; **49**: 337–339.
- 11 Wilson S, Montgomery RD. Local anesthesia and oral surgery in children. In: Pinkham JR, Casamassimo PS, Fields HW, McTigue DJ, Novak AJ. (eds.). *Pediatric Dentistry: Infancy Through Adolescence*, 4th edn. St. Louis, MO, USA: Elsevier Saunders, 2005: 453.
- 12 Malamed SF. Supplemental injection techniques. In: Malamed SF. (ed.). *Handbook of Local Anesthesia*. 5th edn. LA, California, USA: Elsevier Mosby, 1997: 5.
- 13 Froum SJ, Tarnow D, Caiazzo A, Hochman MN. Histologic response to intraligament injections using a computerized local anesthetic delivery system. A pilot study in mini-swine. *J Periodontol* 2000; **71**: 1453–1459.
- 14 Ran D, Peretz B. Assessing the pain reaction of children receiving periodontal ligament anesthesia using a computerized device (Wand). *J Clin Pediatr Dent* 2003; **27**: 247–250.
- 15 Oztas N, Ulusu T, Bodur H, Doğan C. The wand in pulp therapy: an alternative to inferior alveolar nerve block. *Quintessence Int* 2005; **36**: 559–564.
- 16 Ashkenazi M, Blumer S, Eli I. Effectiveness of intra-sulcular computerized-delivery anesthesia in primary molars. *J Am Dent Assoc* 2005; **136**: 1418–1425.
- 17 Ashkenazi M, Blumer S, Eli I. Effectiveness of various modes of computerized delivery anesthesia in maxillary primary molars. *Pediatr Dent* 2006; **28**: 29–38.
- 18 Ashkenazi M, Blumer S, Eli I. Post-operative pain and use of analgesic agents in children following intrasulcular anesthesia and various operative procedures. *Br Dent J* 2007; **202**: E13.

- 19 Acs G, Dranzer E. The incidence of post-operative pain and analgesic usage in children. *ASDC J Dent Child* 1992; **59**: 48–52.
- 20 Clarkson J, O'Mullane D. A modified DDE index for use in epidemiological studies of enamel defects. *J Dent Res* 1989; **68**: 445–450.
- 21 Stewart RE, Horton WA, Eteson DJ. General concept of growth and development. In: Stewart RE, Barber TK, Troutman KC, Wei SHY. (ed.). *Pediatric Dentistry Scientific Foundations and Clinical Practice*. St. Louis: Mosby Co, 1982: 10.
- 22 Williamson JJ. Trauma during exodontia. An etiology factor in hypoplastic premolars. *Br Dent J* 1966; **121**: 284–289.
- 23 Wright JT, Butler WT. Alteration of enamel protein in hypomaturation amelogenesis imperfecta. *J Dent Res* 1989; **68**: 1328–1330.